

## An Effective Orthotic Design for Controlling the Unstable Subtalar Joint

<sup>Carlson</sup>  
J. MARTIN ~~COLSON~~, M.S., C.O.<sup>1</sup>  
GENE BERGLUND<sup>2</sup>

Some 14 years ago, Messrs. W.H. Henderson, J.W. Campbell, and others at the University of California Biomechanics Laboratory gave us the UC-BL shoe insert type of foot orthosis. The concept envisioned in the UC-BL design was excellent. It embodies a design concept that lends itself well to solving a whole range of malalignment and pressure distribution problems of the foot. In the years since 1964, several materials have come to be commonly used in the construction of this orthosis as it has gained wide usage.

Since the advent of the application of the plastic shell design in AFO's and KAFO's, the principles involved in the proper stabilization and support of the pathological foot have gained new and greater recognition as being important. The plastic shell AFO and KAFO give us a "built-in" opportunity to do a superior job of supporting the patient's foot. This cannot be overemphasized. Nowhere is it as true as it is in the field of children's orthotics.

Children with a whole range of neuromuscular disorders demonstrate a large potential and propensity for the development of serious foot deformities. After pes equinus, the most common deformity is valgus instability of the subtalar joint.

The diagram in Figure 1 shows how, in the coronal plane, a simple loss of foot inverter strength is sufficient to precipitate a very unstable and progressive condition. Fortunately, in children, this deformity is often flexible, and proper alignment can be achieved passively.

Unfortunately, the foot support configurations we commonly see in contemporary foot orthoses and ankle-foot orthoses

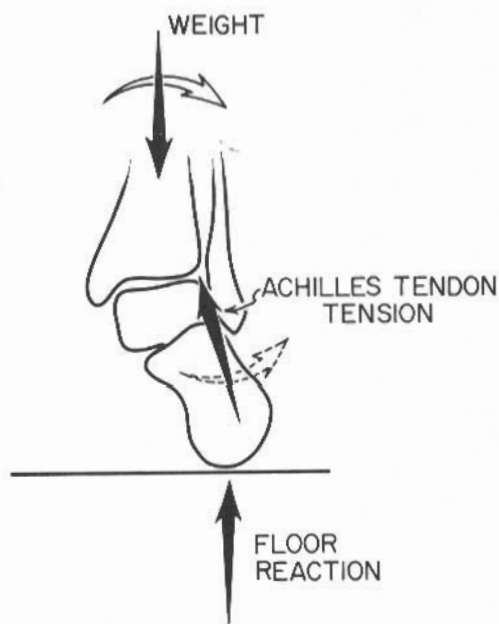


Fig. 1. Destabilizing effects of gravity and Achilles-tendon tension.

for children are not capable of holding the calcaneus in alignment necessary to stabilize the subtalar joint. In fact, it has come to be the opinion of many physicians, after experience with the shoe insert foot orthosis, that the contemporary

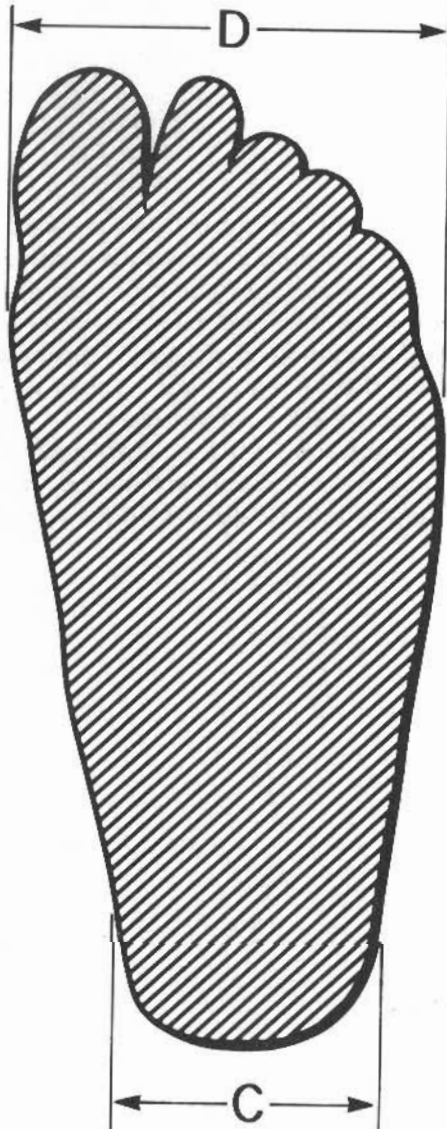


Fig. 2. Medio-lateral measurements of the foot necessary for correction of the plaster positive model.

orthosis is not effective in stabilizing flexible pes valgus when the instability is greater than moderate. This is indeed unfortunate.

We doubt that the problem is the use of inappropriate materials, but rather that the problem usually results from a combination of failure to understand the procedures set forth by UC-BL and failure to develop the design beyond what was originally set forth.

This paper will outline the design principles and procedures used at Gillette Children's Hospital, and present a few examples of short range results.

### DESIGN PRINCIPLES

To create an effective foot orthosis, we must achieve the following:

- Creation of an inner contour for the orthosis which is capable of giving the foot architecture maximum passive support.
- Positive stabilization of the orthosis in the shoe so that it cannot be rolled into a valgus orientation.
- Stabilization of the shoe on the walking surface.

Although the list progresses obviously from most difficult to easiest, all three elements are essential to success, and none can be ignored.

### INNER CONTOUR

Creation of a proper inner configuration begins with an accurate model of the foot. The calcaneus should be well defined in a position of good alignment. The model should possess a longitudinal arch, which needs not to be emphasized anterior to the navicular, since this may cause discomfort while contributing little to the stability of the calcaneus.

There are a variety of procedures and tricks which may be used to obtain a good model. We position the patient supine on a fitting table. The borders of the malleo-

li and the navicular are marked with indelible pencil directly on the skin. We also mark the anterior border of the medial aspect of the calcaneal tuberosity. A piece of surgical tubing is taped longitudinally to the dorsal surface of the foot, and petroleum jelly is applied to the skin avoiding the indelible marks. After applying an elastic plaster bandage, a casting board is pressed against the plantar surface of the plaster covered foot. With one hand, the orthotist grasps the forefoot against the casting board, while the other hand holds the calcaneus in proper alignment. Inward rotation of the foot may also be helpful as outlined in the original UC-BL paper (1). Partial weightbearing is simulated by the orthotist exerting pressure against the base of the casting board.

After obtaining the model, the width of the bare foot is measured at the metatarsal heads and at mid-heel point (Fig. 2). These measurements are taken with the stick pressed against the plantar surface so that a measurement approximating the weightbearing configuration is obtained.

The positive model is smoothed, and the M-L dimension at the metatarsal heads is brought to measurement. The plantar surface at and just proximal to the metatarsal heads and at the heel is flattened precisely perpendicular to the vertical (Fig. 3). In cases where the deformity is severe, it is advisable to flatten the heel at a slight angle (4 deg to 7 deg. depending on severity), by removing more plaster from the medial side. The forefoot is left alone at this point. (It will be shown later how this wedge effect is supported.) Figure 4 illustrates the alignment of the metatarsal and heel flats in the severe case. The M-L dimension of the base of the heel is brought to 0.3 cm. under measurement by removing plaster from the lateral tissue bulge at the base of the heel.

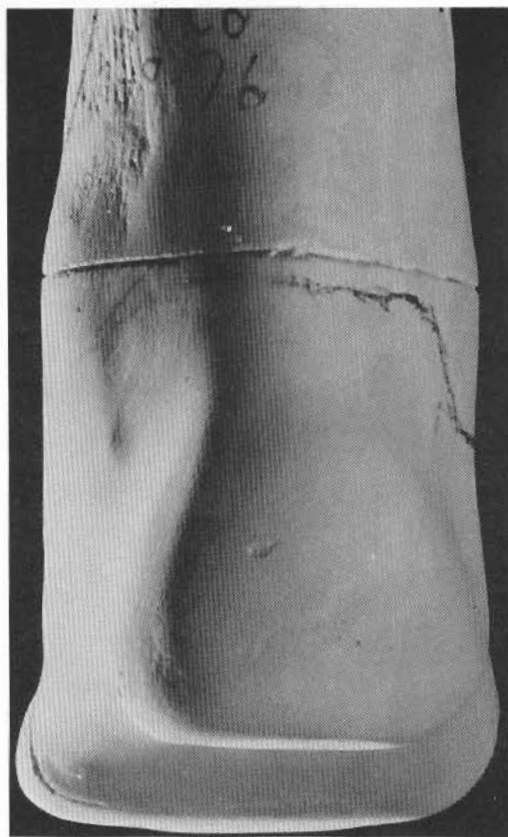


Fig. 3. Posterior view of the positive model showing the orientation of metatarsal head and heel flats.

Perhaps the most important step in cast modification is exaggeration of the posterior aspect of the longitudinal arch (Fig. 5) and blending this in with the medial support area above the calcaneal tuberosity (Fig. 6). At this state, the markings locating the navicular and the calcaneal tuberosity become very important. It is between these two features that it is necessary to remove plaster aggressively in order to create the pressure needed to support directly the calcaneus in the area of the sustentaculum tali (Fig. 7). The amount of plaster removed depends on the size of the foot and the thickness of

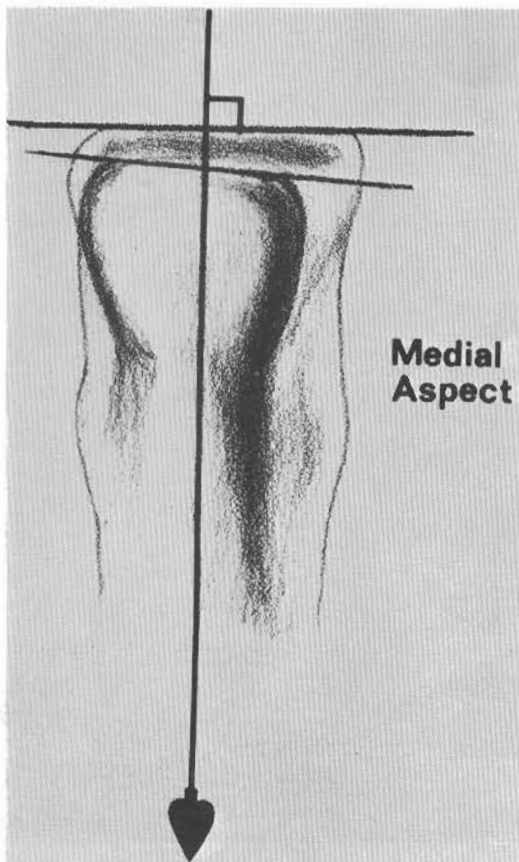


Fig. 4. Diagram illustrating the orientation of the flattened areas in the more severe case. The diagram shows the foot upside down as it would be during modification.

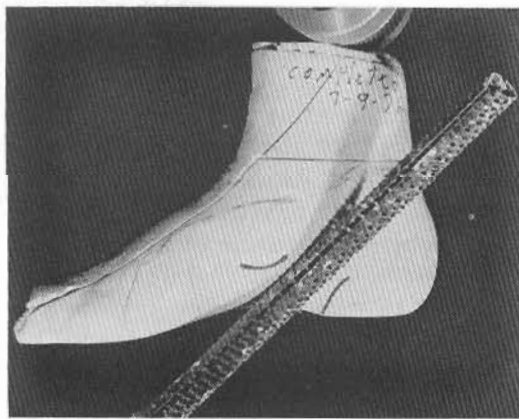


Fig. 5. Exaggeration of the posterior aspect of the longitudinal arch is very important.

subcutaneous tissue. It is not uncommon for us to remove plaster to a maximum depth of 0.8 cm. ( $\frac{1}{4}$  inch) on the model of a juvenile foot. To do this without causing tissue damage requires respect of the borders of the calcaneal tuberosity and, especially, the navicular.

The effectiveness of a good supporting inner contour should never be compromised by an improper trim line. Trim lines on the medial aspect should be as high as is comfortable and practical. On the lateral aspect, they can be considerably lower.

Richard Lehneis (2) pointed out several years ago the disadvantages of supporting the midfoot primarily and relying on medial ligaments such as the spring ligament to transmit this support back to the calcaneus (Fig. 8). It is likely that this (latter) approach will merely result in greater hypermobility of the subtalar joint.

#### STABILIZING THE ORTHOSIS

Positive stabilization of the orthosis in the shoe is accomplished by means of a medial heel extension lump. When the model is covered with hot polypropylene, 0.3-cm. thick, a small piece of hot polypropylene, 0.6-cm. thick, is pressed onto the medio-plantar aspect of the heel portion of the first layer. The result is an extra lump of material fusion-bonded to the outside of the shell. Later, when the assembly has cooled and frozen, the lump is ground down to square it off as shown in Figure 9.

Figure 10 is a cross-section of the foot orthosis without the medial heel extension. As the foot tends to roll the orthosis into valgus, the orthosis will tend to tip up and roll over the point of most medial contact. A resisting moment ( $W$  times  $r$ , the distance of that point from the weight line) will tend to prevent this from happening. As can be seen from the diagram

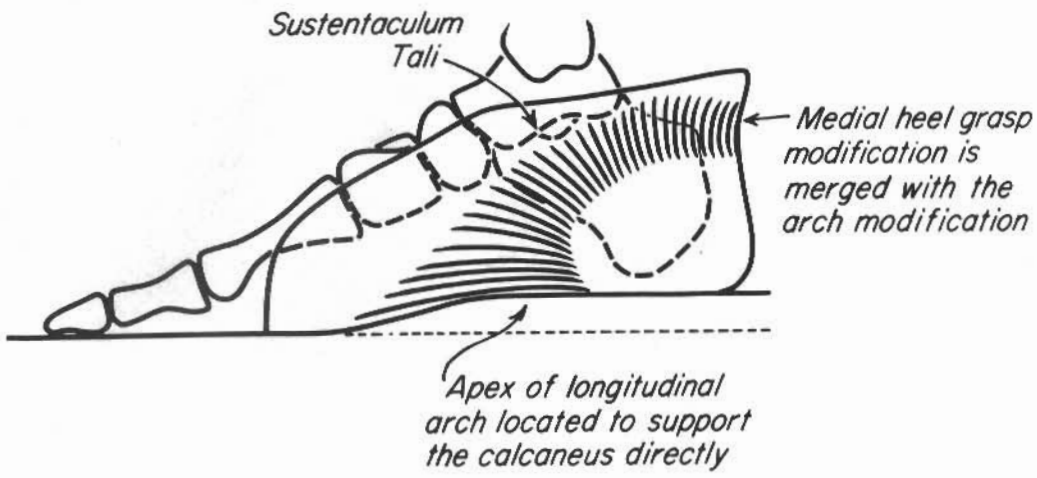


Fig. 6. Diagram of medial support areas.

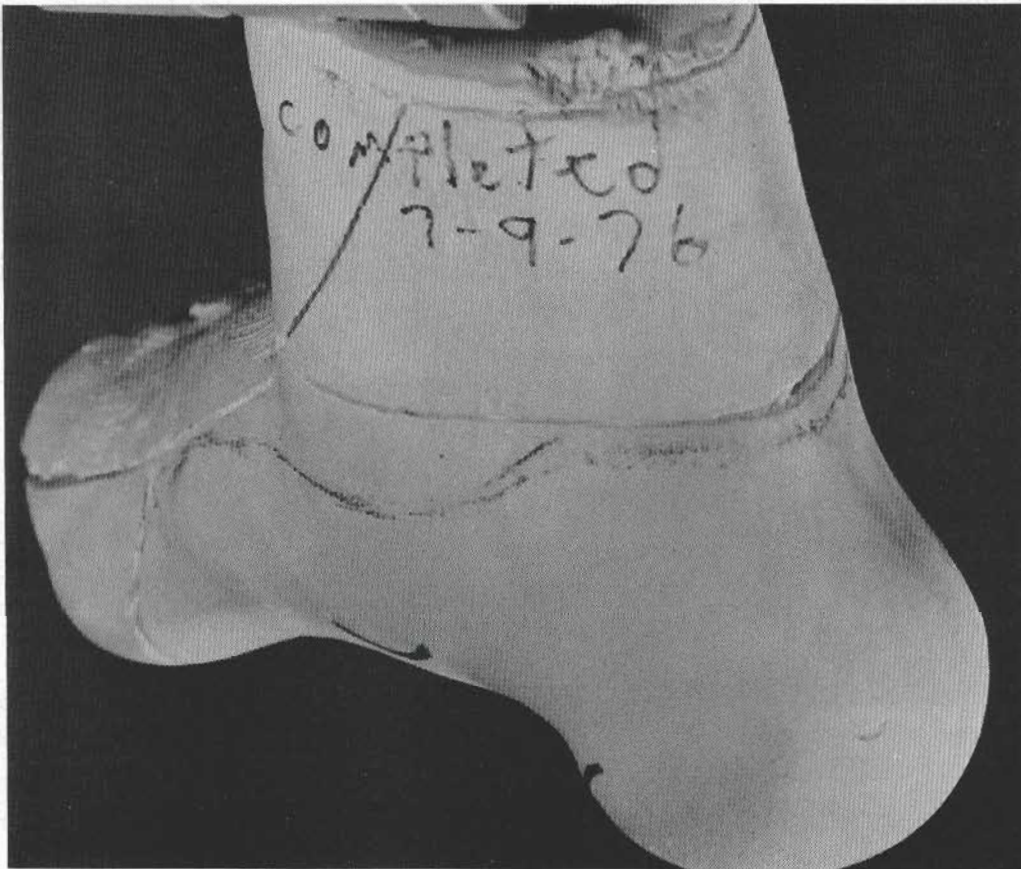


Fig. 7. Photograph showing the surface contour of the medial support area.

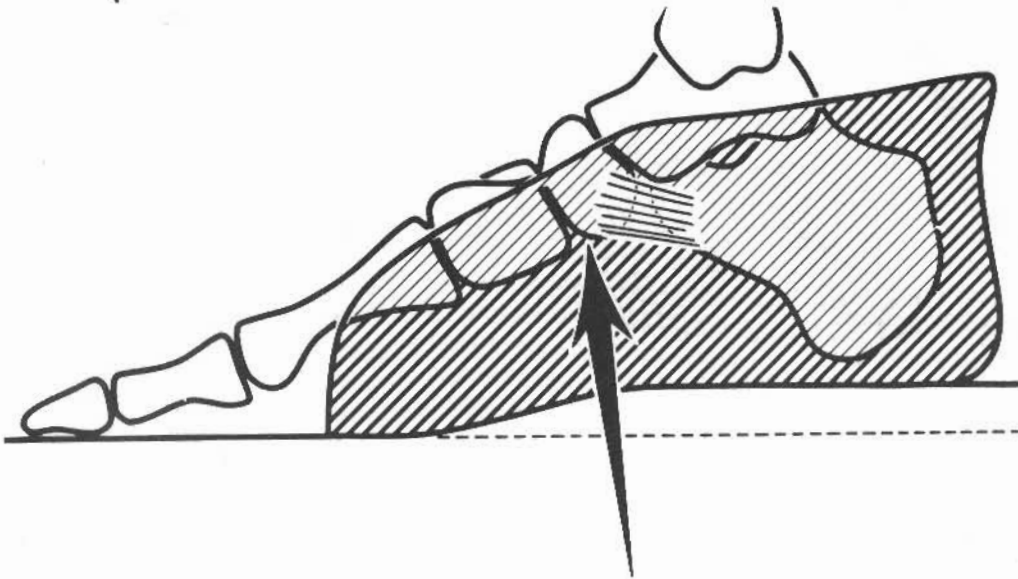


Fig. 8. Apex of arch centered in the area of the navicular. Support must be transmitted to the calcaneus via the spring and other medial ligaments.

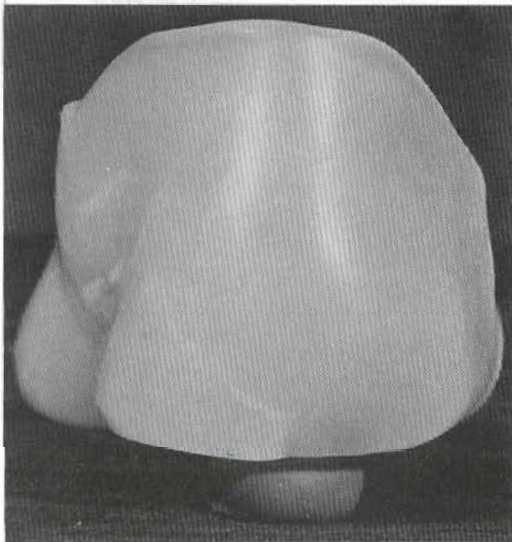


Fig. 9. Photograph of the medial heel extension.

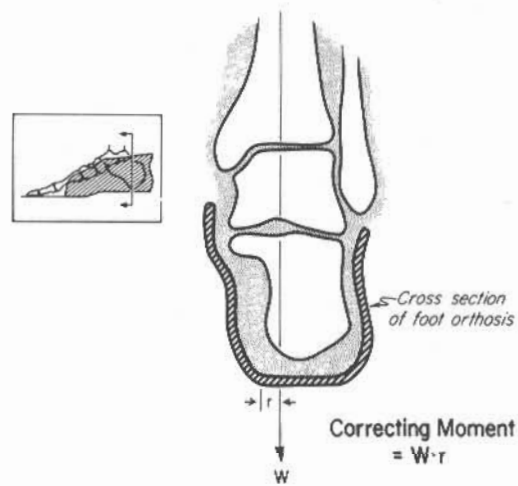


Fig. 10. Cross-section through the heel area of the Shoe Insert Type Foot Orthosis as commonly provided.

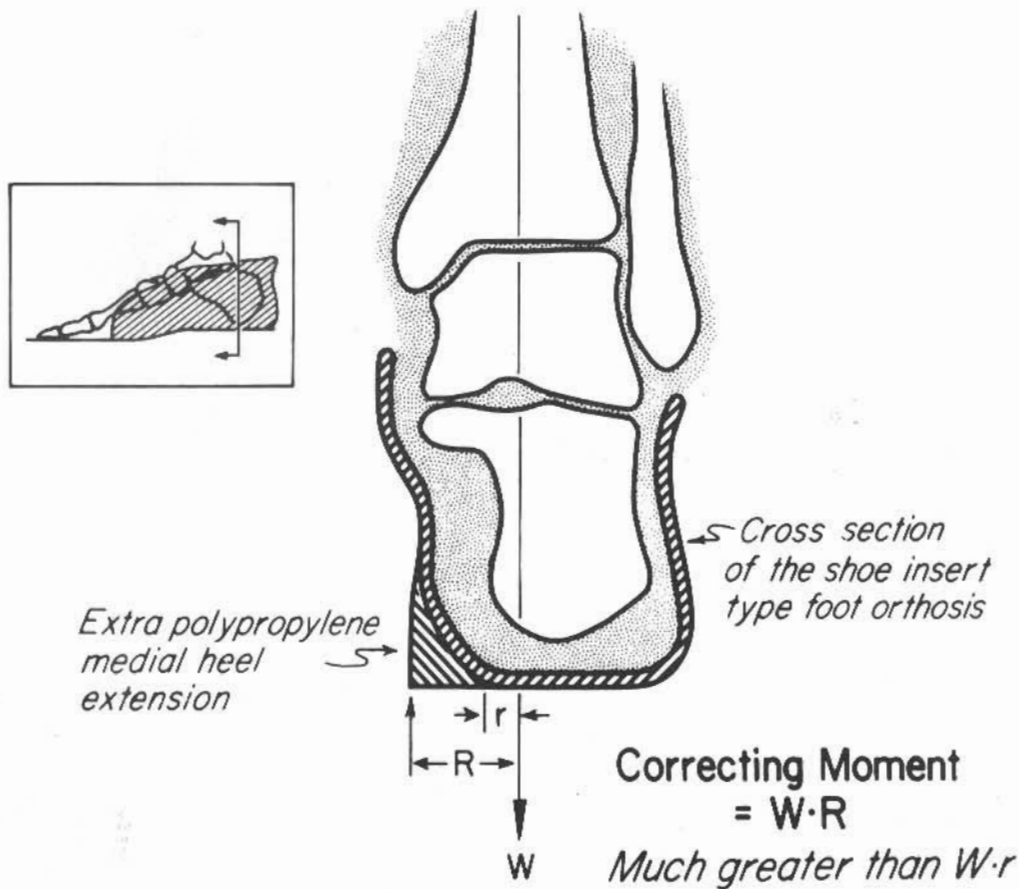


Fig. 11. Stabilizing effect of the extension on the medial aspect of the heel of the Foot Orthosis.

of Figure 11, the addition of the medial heel extension significantly increases the moment arm,  $R$ , and it has much greater resistance to being rolled into valgus.

In those more severe cases where we have angled the heel medially, the polypropylene which we added to create a medial extension is utilized also as a wedge (Fig. 12). This wedge should be equivalent to the amount of plaster removed from the medial plantar aspect of the heel during model modification. It extends part way under the heel supporting the orthosis in the correct alignment.

When treating a varus instability, the inner contour of the orthosis will not contain the medial calcaneal support feature, and the extension will be placed on the lateral side of the heel instead of the medial side.

Robert Nitschke (3) has also been using a medial heel extension, but his have been on a design using Orthoplast.

#### STABILIZING THE SHOE

Stabilizing the shoe on the walking surface is usually not a problem if everything

else has been done correctly. The children seen here wear a wide variety of shoes with their foot orthoses including tennis shoes. We do tell our patients to avoid shoes with narrow heels, especially those made of the softer materials, because such heels may allow the entire foot-orthosis-shoe complex to roll quickly into valgus.

## RESULTS

We at Gillette Children's Hospital are pleased about the results we have been getting with this design during the past two years. Most of the children we treat have long range orthopedic problems, and preventing or at least minimizing foot deformities in these children is also a long range endeavor. It should begin certainly while the deformity is still flexible and bone deformities are still minimal. Treatment probably should continue until the deforming forces have been alleviated in the bare foot or through the end of growth, whichever comes first. Perhaps this is a good time to point out that although this foot orthosis does find some application in club foot and other congenital foot deformities, this paper discusses application in the more flexible deformities generally acquired after birth.

Figure 13 is the photograph of the foot of a six-year-old child with myelomeningocele. Although her deformity is serious, the calcaneus can still be brought into good alignment (Fig. 14). The photos of Figures 15A and 15B show her moments later in her orthosis. Although her shoe and orthosis obscure the view of her foot, there seems little doubt about the improvement.

Figure 16 is a photograph of the feet of a ten-year-old child with a glycogen storage disease. Again the deformity is quite severe, but flexible. Figure 17 shows two views of him standing in his orthoses.

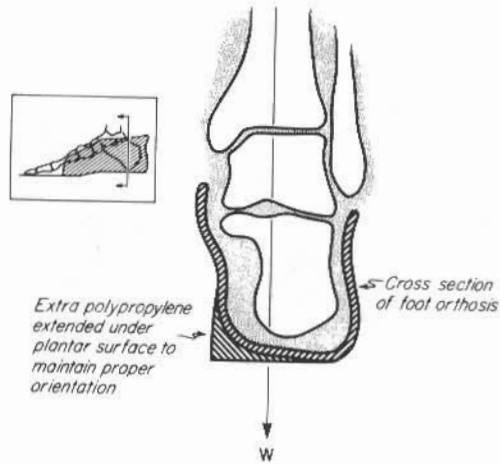


Fig. 12. The polypropylene medial heel extension is ground flat on a horizontal plane to create a wedge supporting the orthosis in proper alignment.

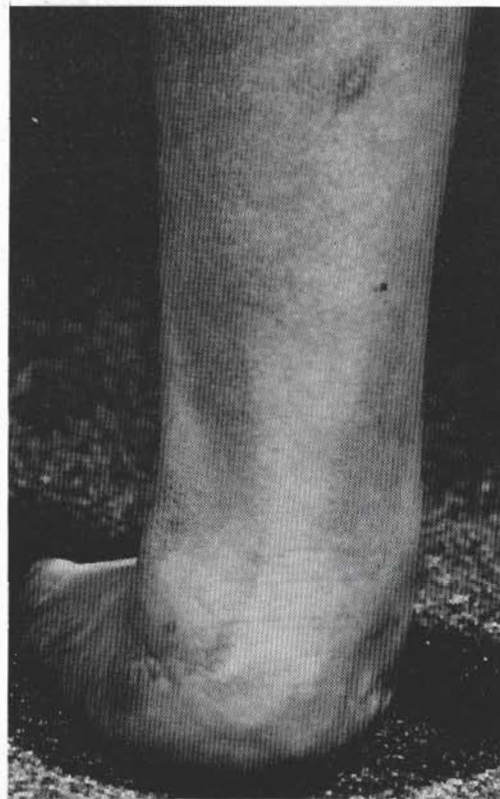


Fig. 13. Photograph of the weightbearing foot of a six-year-old child with myelomeningocele.

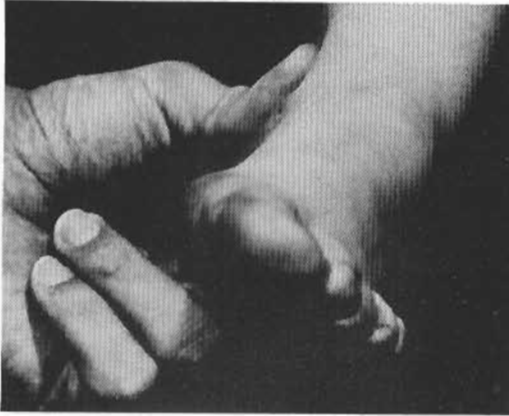


Fig. 14. Illustration of the flexibility of the foot deformity in the six-year-old child.

Probably better than 80 percent of our patients who require orthotic treatment across the ankle or across the knee and ankle possess a potentially serious valgus instability of the subtalar joint. The techniques outlined for generating a supporting inner contour are used to equally good advantage in our plastic AFOs and KAFOs. Proper alignment and support below the subtalar joint reduces or eliminates the need for valgus corrective straps and padding above the ankle.

The purpose which the outrigger lump serves on the FO is generally, of course, not appropriate on the AFO or KAFO.

Finally, the subtalar joint also exhibits some plantar and dorsiflexion motion

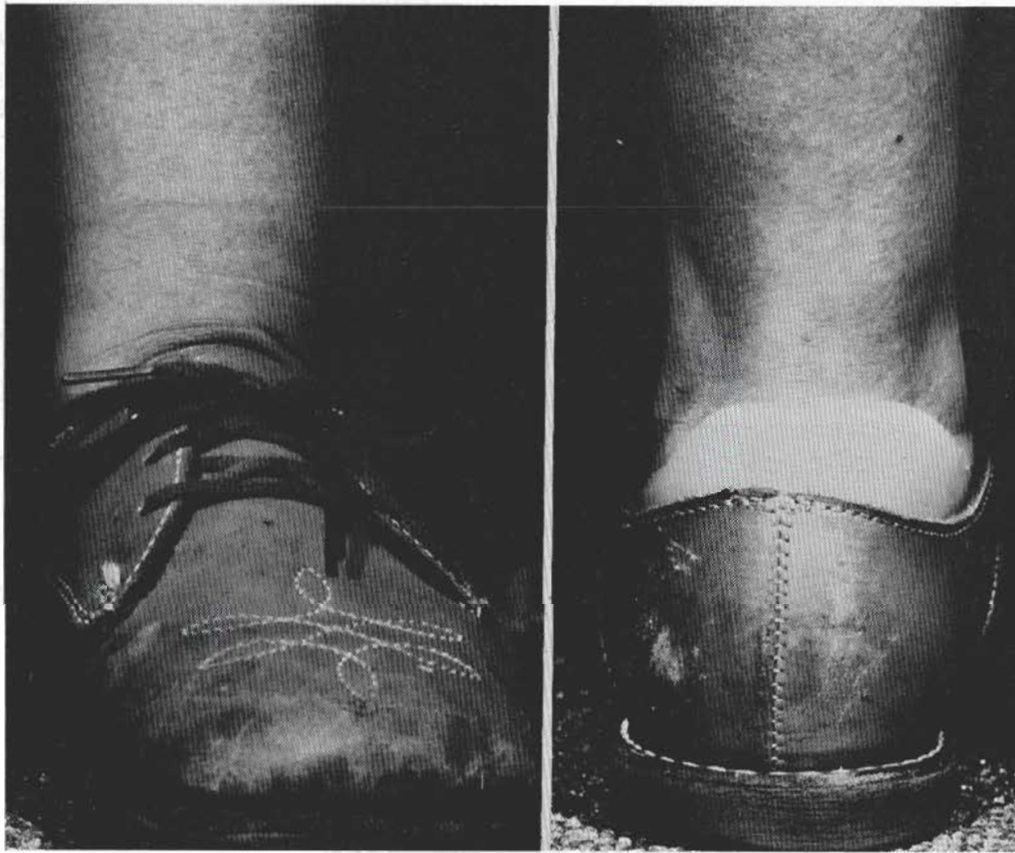


Fig. 15. Photographs of the same six-year-old in her Foot Orthosis and shoe.

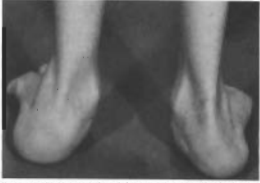

Fig. 16. Photograph of the weightbearing feet of a ten-year-old child with a glycogen storage disease.

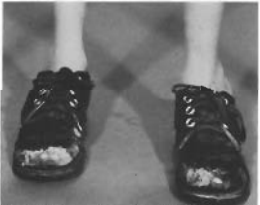
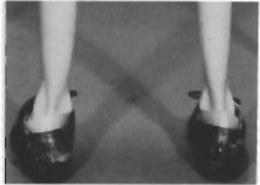
Fig. 17. Photographs of the child of Figure 15 wearing his F661 Orthoses and shoes.

and transverse rotation. We do not want to leave this subject without commenting briefly on what happens in the sagittal plane.

The top view in Figure 18 is the lateral weightbearing X-ray of the bare foot of the girl in Figures 13, 14, and 15. The navicular is in very close proximity to the floor, and it can be seen easily that the calcaneus and talus are in a relatively plantar-flexed position.

The bottom view of Figure 18 is an X-ray moments later of her foot in the orthosis and bearing weight. Weight-bearing forces have obviously been shifted forward and medially off the tuberosity of the calcaneus. The distance from the navicular to the insole has been almost doubled. The flesh pad under the calcaneal tuberosity is now almost twice as thick, proving decompression, but the calcaneus and talus are still relatively plantarflexed. Obviously, this aspect of the deformity is not as flexible as the valgus instability.

When plantarflexion of the calcaneus is due to spastic plantar-flexor muscles, it is pretty clear that both surgical and orthotic treatment are required for correction. This child does not have this problem, and tight ligaments are probably preventing the hind foot from assuming a more dorsiflexed position with respect to the forefoot. It will be interesting to see if these ligaments loosen with time, allowing the talus and calcaneus to assume a more normal dorsiflexion angle.

#### ACKNOWLEDGMENTS

The authors wish to acknowledge the contributions made by the other members of the Orthotic and Prosthetic Laboratory at Gillette Children's Hospital. The sketches and diagrams were by Carol Novak. The photography was by Ken Jandl and Gordon Dunn.

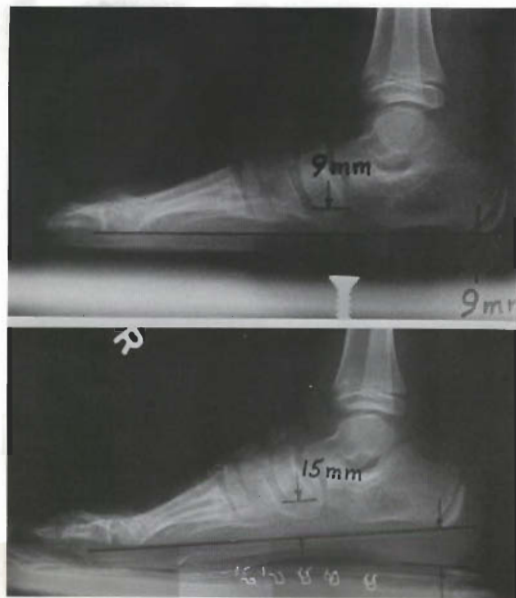


Fig. 18. Lateral weight-bearing X rays of six-year-old patient shown in Figures 12, 13, and 14 in lateral weight-bearing without orthosis (top) and with the orthosis (bottom)

**References Cited**

- (1) Henderson, W.M., and J.W. Campbell. *U.C.-BL shoe insert - casting and fabrication*. Bulletin of Prosthetics Research. BPR 10-11, Spring 1969, pp. 215-235.
- (2) LeFevre, Richard. Institute of Rehabilitation Medicine, 409 East 34th Street, New York, N.Y. 10016.
- (3) Nischler, Robert D., Rochester Orthopedic Laboratories, 1634 Monroe Avenue, Rochester, N.Y. 14618; personal communication.