

Description for New Overall Balance: Summation for the Conservative Treatment of Idiopathic Scoliosis in Determining Orthosis Design

■ By Marty Carlson, CPO, FAAOP and Keith M. Smith, CO, LO, FAAOP

Abstract

Currently, the Cobb angle is accepted as the gold standard in predicting success or failure in managing adolescent idiopathic scoliosis. The authors are presenting a new summation that would go a step further by giving the practitioner a quick and reproducible tool to map out orthosis design and application of forces. The goal is to increase balance quantitatively of the spinal column in relation to the central sacral line (CSL). The new summation does not negate the need for the Cobb angle but simply adds another tool for determining effectiveness from the application of forces.

Key Words

Decompensation, trunk shift, overall balance summation (OBS), lateral deviation from midline (LDM), coronal plane

Introduction

To quote a recently published *JPO* editorial, "We can probably agree that, in North America, the primary goal of orthotic treatment of AIS is to prevent the youngster's spine deformity from becoming severe enough to trigger a decision for surgical fusion.¹ Within the realm of that goal, our aim should be to minimize and stabilize the deformity in an optimally compensated and aligned configuration in order to achieve the best cosmetic result for the youngster. An optimum cosmetic result is not most directly served by minimizing the Cobb angle of each and every curve to the extent orthotically possible." Capasso et al. suggest that there exists about 90 methods of measurement to qualify as scoliosis.² In another article, the authors recognize that evaluation that is based on only one of these is not reliable because a spinal curve is only partially defined by the angular measurements.³ The Cobb angle is a quick and easy way to measure the magnitude of individual scoliotic curves, but it is poorly suited for the assessment of cosmetic factors.

In addition, the Cobb angle does not account for trunk shifts and decompensations from the CSL.

The quality of conservative treatment protocols and orthotic design is ultimately limited by the validity of our measurement tool. The limitations of Cobb angle numbers have to do with the fact that those measurements relate to individual curves. The Cobb angle doesn't tell us how far the spine deviates from optimum alignment at any level. Watts emphasizes the importance of the mass of the body superior to the pelvis being centered over the pelvis.⁴ Bassett and Bunnell emphasize the need to pay attention to trunk shift and show that in 80 patients, after treatment with a Wilmington TLSO, lateral trunk shift was improved in 58 percent of patients with thoracic curves, 65 percent with thoracolumbar curves, and 88 percent with double major curves.⁵ A more valid way to quickly measure

and objectively evaluate cosmetic alignment of the compensation/balance component is being proposed here. The use of measuring from the center of each vertebrae throughout the entire spine to the CSL was proposed in which all the values were recorded and compared to each other.⁶ While effective, the limitation still remains that a quick reference that is easily reproduced in the clinic setting would be more practical. If we can develop and teach a more valid measurement, based on this relationship to the CSL relative to these coronal plane deviations, orthotic designs and treatment decisions will naturally evolve to better serve the AIS patient. A combined value that would describe these relations to the CSL could lead to what the authors refer to as overall balance summation (OBS).

Blount, Bidwell, Schmidt, and Moe, the early pioneers in effective orthotic treatment of idiopathic scoliosis recognized what they called "compensation" and "balance" and its relationship to cosmesis. Optimal compensation and balance results in the head and shoulders centered in the frontal plane, over the sacro-pelvic complex. Watts also recognized patients who exhibited good compensation with C7 centered over the pelvis in the coronal plane and still exhibited a trunk shift away from the CSL.⁴ Level, centered shoulders help shirts, blouses, and dresses drape evenly. When well balanced, even sizable double curves cause no significant cosmetic problem. This requires a kind of "matching" within the family of scoliosis curves not adequately indicated by Cobb-angle values. For instance, two 40-degree curves may or may not be well balanced in relation to the CSL. Therefore, equal Cobb angles do not necessarily indicate good balance.

As idiopathic scoliosis treatment has become more and more dispersed, attention to these compensation/balance factors has declined. There seems to be a creeping tendency to maximize correction of each and every curve; treat curves instead of patients. For instance, we have seen scientific program and instructional course presentations that show radiographs of supposedly successful orthotic treatment in which cosmetic factors and coronal plane deviations are clearly overlooked or ignored. Here are three examples of this:

1. A left-only thoracolumbar curve treated with both a left lumbar pad and a right thoracic pad resulting in an 80-percent Cobb angle reduction. The treating orthotist was oblivious to the fact that his aggressive right thoracic pad increased leftward misalignment of the patient's thorax, neck, and head.
2. A right thoracic and left lumbar curve combination are both aggressively treated. "Good" correction is achieved on the right thoracic curve and "magnificent" correction

on the left lumbar curve. No comment is made regarding the creation of a new, high left thoracic curve, a high left shoulder, and a leftward misalignment of C7.

3. A right thoracic, left lumbar curve presenting with the entire CTL spine misaligned leftward of the CSL. An orthosis with a combination of left lumbar and right thoracic forces did dramatically reduce both Cobb angles, but the right thoracic force dominated alignment. The treating orthotist made no comment about the fact that leftward misalignment of the entire CTL spine was worse in the orthoses than before treatment.

Overall Balance Summation

To determine the overall balance summation (OBS) the procedure is as follows:

1. Align the P-A radiograph vertically in the view box.
2. Use a "T" square (crossbar against the bottom edge of the view box) to draw a vertical line on the radiograph from the center of the sacrum upward to at least the level of C7. This is the CSL. Another effective way to find the CSL is to bisect the sacrum and measure from this point to the side of the radiograph. Then use this measurement to measure from the side of the radiograph to a point at around T1. Connect these points.
3. Place a small vertical line marking the center of the body of each of the apical vertebrae and C7.
4. Measure the lateral deviation from midline (LDM) (rightward "+" or leftward "-") of the centers of vertebral bodies at each curve apex and at C7 (or the most appropriate cervical level, if different). For example, let us say those measurements are -3mm at C7, +20mm at T8, and -22mm at L1 for a youngster with a right thoracic left lumbar curve combination.
5. Those three values could be added (-3mm + 20mm + -22mm = -5mm) to yield a single number that conveys a fairly accurate sense of how well that spine is balanced/aligned. This process requires about the same amount of time as measuring the Cobb angles.

In the notation proposed here, the first value always represents the lateral deviation of C7 in relation to the CSL. The second value represents the lateral deviation of the center of the body of the apical vertebrae of the superior curve. Subsequent values relate similarly to lower curves in descending order.

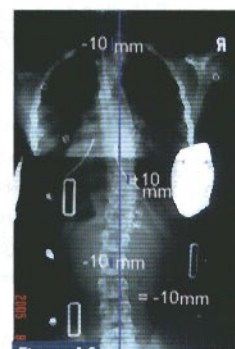
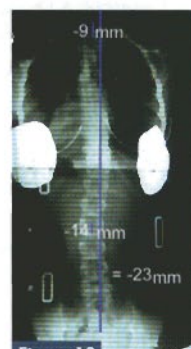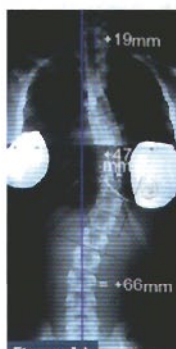The use of this summation need not displace or disregard the use of the Cobb angle measurement. Rather it serves to help orthotists and surgeons design treatment and judge progress. The Cobb angle may still be used to determine the initiation of orthotic treatment or when surgery is necessary. This OBS recognizes the central sacral line (CSL) as the ideal and desired alignment of the entire spinal column and is a computation of how balanced the deformity is about that ideal. Keeping in mind the necessary measurements are the lateral deviation of C7 and the left or right lateral deviation of all curve apices, the resultant measurements are then added together to give a value that emphasizes the overall balance as well as being a guide for application of orthotic forces.

The *JPO* editorial¹ referred to earlier diagrams and examples of how to measure and calculate the OBS for single curves, double curves, and triple curves. We will now use several real examples to illustrate this.

Patient 1

The patient presented (figure 1A) with a right thoracic curve of 38 degrees. With the CSL clearly marked on the radiograph, we immediately see that most of our corrective force should be from right to left and that a compensatory left lumbar curve would create better balance. The lateral deviation of C7 is 19mm rightward, and the thoracic curve apical body is +47mm rightward. That yields a very unbalanced OBS value of +66mm. This patient was fitted with a TLSO thermoformed over a mold taken on the Risser table with a force at the thoracic curve and also a shift of the trunk to the left relative to the pelvis. This shift is applied by a gluteus medius push on the left and an opposite force on the trunk to bring it closer to the midline. This style of molding is presented as a simple coronal plane translation of the trunk above the pelvis paying particular attention to the distance of the apical vertebrae to the CSL.⁶ The in-orthosis radiographs (figure 1B) revealed the Cobb angle corrected from 38 degrees to 17 degrees, and a compensatory curve of 15 degrees was created in the lumbar region. Lateral deviation values were measured again at C7 and curve apices including this new compensatory lumbar curve. The new values are -9mm, 0mm, and -14mm. The resultant summation then would be -23mm.

Radiographs were again taken in orthosis two months later (figure 1C), which revealed Cobb angle measurements of 22 and 14 degrees with lateral deviation values of -10mm, +10mm, and -10mm (OBS = -10). It should be noted, however, that this example illustrates yet another principle of scoliosis treatment: numbers can never tell us all. The spinal orthosis seems to be causing the right shoulder to be significantly higher than the left. It is likely that the right axillary border of the orthosis should be lowered.

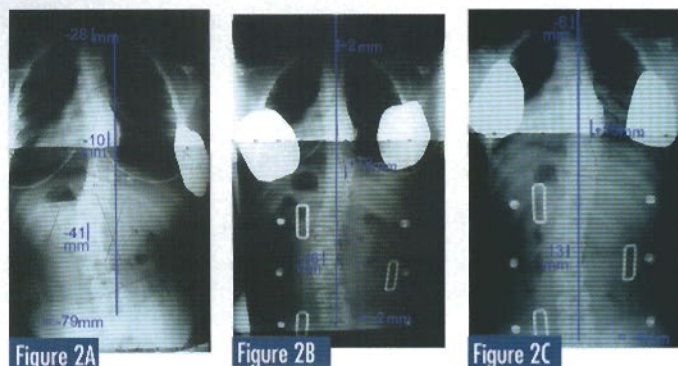


Patient 2

Patient number 2 presented with a double curve—right thoracic and left lumbar (figure 2A). The CSL on the radiograph clearly shows leftward malalignment of the entire supra-sacral spine. Even the apex of the right thoracic curve is located to the left of CSL. This means that even though the curves have equal Cobb angles, our

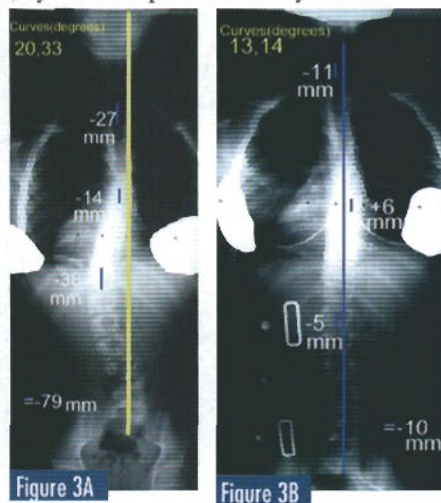
therapeutic forces must predominantly be from left to right. Stabilizing the orthosis will be a challenge, and the method for achieving this is described later.

The first in-orthosis radiograph (figure 2B) indicates that the orthosis is very successful. The Cobb angles have been reduced from 36 degrees and 36 degrees to 28 degrees and 23 degrees. A good, balanced alignment has also been achieved. The LDM measurements are +2mm, +12mm, and -16mm, so the OBS is -2mm. A radiograph two months later (figure 2C) to monitor progress indicates that the orthosis continues to do an excellent job.



Patient 3

Patient number 3 presented (figure 3A) with a 33-degree left thoracolumbar curve inadequately compensated/balanced by a 20-degree right thoracic curve. The LDM measurements are -27mm, -14mm, and -38mm. The overall balance summation is -79mm. The overall alignment, by visual impression and by the OBS calculation, calls for orthotic forces applied to the left lumbar and left lower-thoracic elements. Very little, if any, orthotic holding force should be applied to the right mid and upper thorax. Once again, the in-orthosis radiograph shows excellent early results (figure 3B).



Application of Forces

It is important to note that the directly therapeutic/corrective forces applied toward the spinal column are not the only forces we must design into the orthosis. The other set of forces are those necessary to stabilize the orthosis. For instance, when the corrective forces are predominantly left-to-right, as in patients 2 and 3, we must design for a fulcrum on the right side of the pelvic section just distal of the iliac crest and a left trochanteric extension. These forces stabilize

the orthosis, preventing it from being tilted leftward by the patient's leftward misalignment. The State of the Science Conference document on scoliosis presents this principal in further detail on page S25-26.⁷ An illustration of the shifting procedure has been presented previously depicting the application of these forces.⁶

Conclusion

The authors are not advocating LDM measurements and the OBS for use with neuromuscular scoliosis. For that reason and others, the Cobb angle will most likely continue to be the foremost measure of scoliosis severity.

The CSL is extremely useful as a qualitative visual indicator of where orthotic forces need to be exerted. Measuring the LDMs and calculating the OBS is the next step in using the CSL. The authors propose that these give the practitioner the most valid quantitative tool for judging, recording, and developing conservative treatment methods in orthosis design.

The authors advocate the use of LDM measurements and the OBS value to better monitor orthotic treatment progress and outcomes for patients with idiopathic scoliosis. We feel it gives more consistently valid information/numbers for that purpose than does the Cobb angle measurement. OBS monitoring and reporting will inevitably improve treatment and outcomes for idiopathic scoliosis patients.

The authors propose that a formal study should be undertaken to more thoroughly examine the validity, reliability, and sensitivity of the measurement techniques presented here.

References

1. Carlson, M. Guest Ed: Treatment of Adolescent Idiopathic scoliosis. *J Prost Orth* 2007;19:3:64-66.
2. Capasso, G., Testa, V., Maffulli N., Variability in Cobb Angle Measurements. *J Bone Joint Surg Br* 1996;78(B):339-340.
3. Cappasso G, Maffulli N, Testa V., The Validity and Reliability of Measurements in Spinal Deformities: A Clinical Appraisal. *Acta Orthop Belg* 1992;58:126-35.
4. Watts HG. Bracing in spinal deformities. *Orthop Clin North Am* 1979;10:769-785.
5. Bassett GS, Bunnell WP. Effect of a thoracolumbar orthosis on lateral trunk shift in idiopathic scoliosis. *J Pediatr Orthop* 1986;6:182-185.
6. Smith K. Coronal Plane Trunk Shifts and Decompensational Perspectives in a New Design of an Asymmetrical TLSO Module. *J Prost Orthot* 2004;16:16-22.
7. Katz D, Gavin T, Carlson J, Hooper CR, Smith K, Hentges C, Walker C. Orthotic Treatment Of Idiopathic Scoliosis. *J Prost Orthot* 2003;15;4: S24-S26.

Coming in the
February 2008 issue:
Society Education
by the Lower-Limb
Prosthetics Society.



Log on to the
ONLINE LEARNING CENTER
to complete the quiz
and earn PCE credits.