

Mobility Aids and Prostheses For a Child with Four Anomalous Limbs

Karen Beck, R.P.T.
J. Martin Carlson, M.S., C.P.O.
Richard J. Johnson, M.D.

A child with a complex physical disability requires the involvement of many health care professionals. This review of the management of the prosthetic and mobility needs of an infant with four anomalous limbs underscores the need for full cooperation among all those team members.

SF was seven months old when first

referred to Gillette Children's Hospital for an assessment of her developmental and orthopaedic needs. She came from a generally rural area over 400 miles from the hospital. Both of her upper extremities were absent at the shoulder except for fleshy nubbins approximately one inch long. Both femora, both fibulae, and the lateral two rays of both feet were also ab-

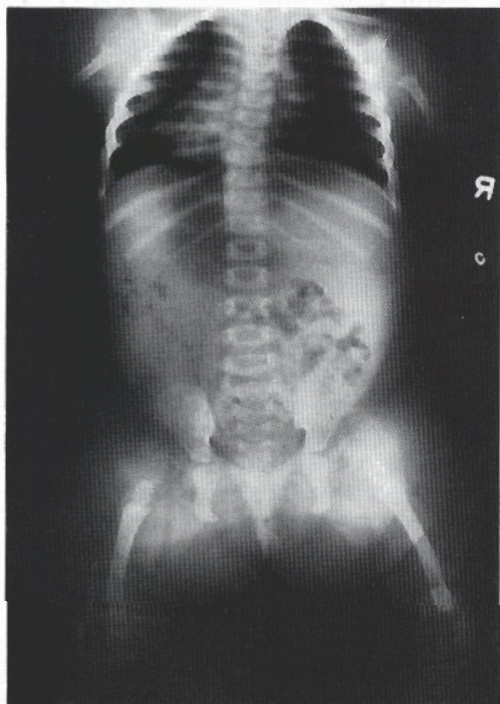
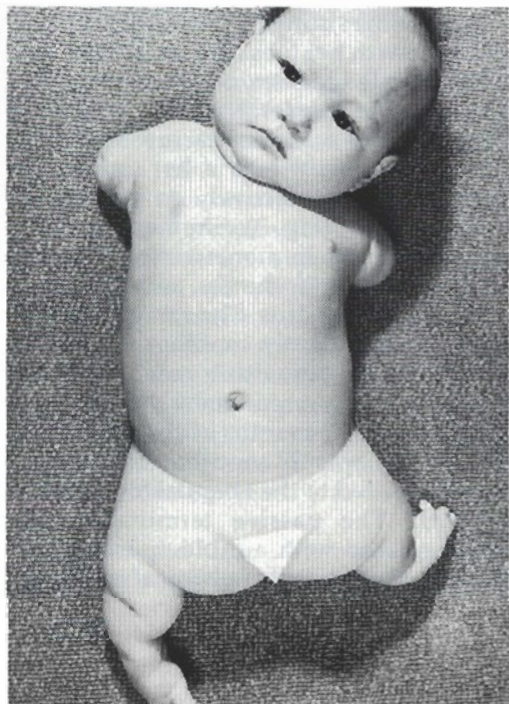


Fig. 1. Patient SF at seven months of age. Both upper limbs were missing except for fleshy nubbins about one inch long. Both femora, fibulae and the lateral rays of both feet were also absent.

sent (Figs. 1a and 1b). According to her medical chart, SF was delivered vaginally and her APGARS were ten at both one minute and five minutes. Her mother had been taking monthly prophylactic penicillin injections for rheumatic fever. No neurological or other medical problems were noted.

When SF was nine months old, a developmental assessment was done by a team consisting of a speech-language pathologist, an audiologist, an occupational therapist, a physical therapist, and a genetic counselor. At that time, her social intellectual and communication skills were considered to be within normal limits. She had good head control and rolled well, but was unable to sit independently. She attempted to manipulate toys with her tongue, her toes and her shoulders. Because of her inability to sit, she was provided with low posterior and lateral trunk support by a block of carved Ethafoam^{®1} covered with Plastazote^{®2}. An overhead bar was attached to the base from which to suspend toys, which she could then explore with her mouth (Fig. 2). She used this support at home until she acquired independent sitting balance, at approximately 12-14 months of age. No upper extremity prostheses were fabricated because they may have hindered her mobility and deprived her of sensory input.

SF was seen again when she was 16 months old. She manipulated toys with the toes of both feet, although she was more dextrous with the right. She also had learned to grasp objects quite successfully between her chin and shoulder on either side. Inasmuch as she had achieved sitting balance, she was considered a good candidate for an upper extremity limb so she was fitted with a left shoulder disarticulation prosthesis with a fixed elbow and passive hand. The passive hand was interchangeable with a passive hook. It was placed on the left to facilitate her using it in combination with her dextrous contralateral toes. An occupational therapist worked with SF in the use of her new limb daily for about one week and she began to use the prosthesis to push and pull objects that were positioned in the terminal devices for her.

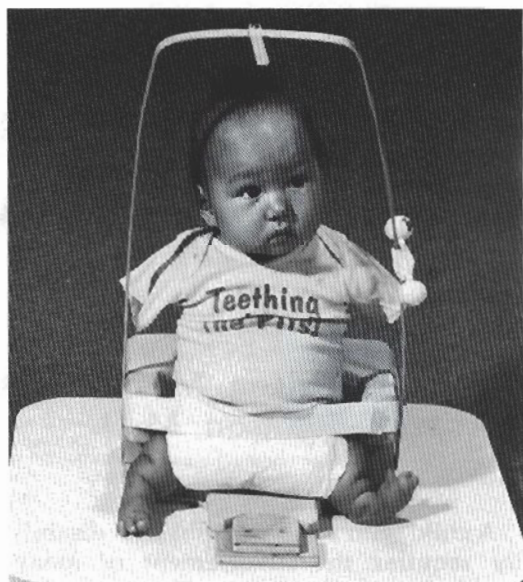


Fig. 2. A trunk support was designed to provide sitting balance at nine months of age. Toys were suspended from the overhead bar so she could explore with her mouth.

Except for rolling, SF had not developed independent floor mobility at the age of 16 months. She made unsuccessful attempts to scoot while sitting by pulling on the floor or carpet with her toes. A special caster cart was fabricated for her, on which she could sit suspended several inches above the floor. The seat was very narrow so that her feet were directly below her trunk, and could be used effectively to propel and steer her "car" (Fig. 3). She became amazingly proficient in maneuvering it, going rapidly, stopping shortly and turning it within its own radius. The cart enabled her to be independently mobile on the floor while keeping her within reach of toys. It was still being used many hours a day when SF was 29 months old.

When SF was 23 months old, she was again admitted to the hospital for prosthetic work. The passive terminal devices were replaced with a cable-operated one. Because of a scarcity of physical or occupational therapy services in her community, training in the use of the new limb in the hospital was recommended, but it was impossible to arrange for that. Therefore, she did not make optimum use of this first cable-operated upper limb.



Fig. 3. At sixteen months of age a special caster cart was developed to allow independent mobility.

When seen again at the age of 29 months, SF had begun to lift herself to stand at a chair or table and maintain that position by leaning her trunk against the supporting surface. She was fitted with short bilateral lower extremity extension prostheses to provide stability for stance, as seen in Figure 4. She was seen in the physical therapy department for training in their use. After approximately two weeks, she was able to walk five feet without external support or assistive devices and some times independently came to stance from a sitting position. It was anticipated that she would use them primarily for indoor mobility.

At the same time a left above-elbow prosthesis was fitted (Fig. 4). It had a passive constant friction elbow and wrist unit and a functional model 12P terminal device. An occupational therapist worked with her daily for three weeks, during which SF learned to use the prosthesis to manipulate pegs, formboards, pullstring

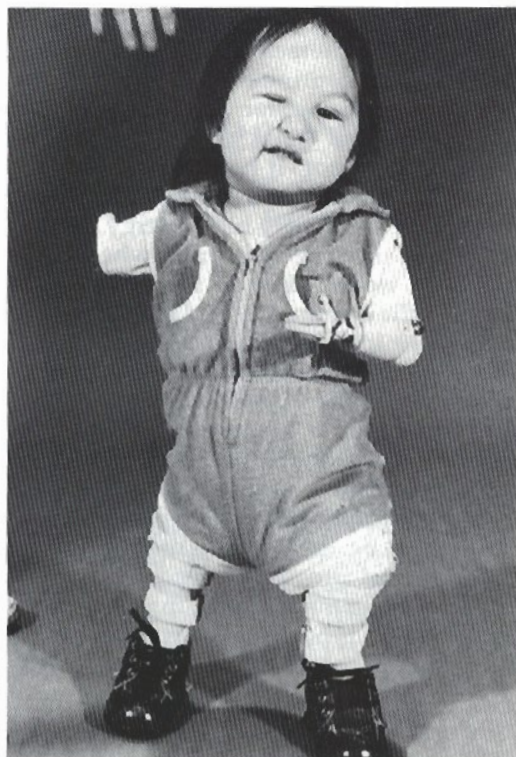

Fig. 4. At twenty-nine months of age a left above elbow prosthesis was provided along with lower limb extension prostheses.

toys and nesting boxes with some assistance. She also began to learn to position objects in the limb with the toes of her right foot, although the terminal device had to be prepositioned for her.

During the same hospital admission, an A-Bec Fireball^{®3} powered wheelchair was made available for several days' trial. The control box was positioned within reach of SF's right lower extremity digits and it was "geared down" to its slowest speed. After approximately six 15-minute sessions of physical therapy, she mastered maneuvering it. If funding is approved for purchasing such a chair for SF, adaptations will be made to seat her securely and at the proper height to reach the control stick.

SF's mobility needs can be met by combining the use of the special caster cart, the lower extremity prostheses, and the powered wheelchair. There is considerable potential for SF to become proficient in the use of the lower extremity prostheses. They may become her primary means of indoor,

and even possibly outdoor mobility. In later years, she herself will have to decide if she wants to continue with them. At her young age, the caster cart provides her with speed and quick access to toys and peers on the floor. It has limited use outdoors because of the wear and tear on her feet and the relatively high energy needed to propel it. The powered wheelchair, however, would allow SF to move around freely in the community and place her high enough to interact with other persons. It would be most beneficial for movement in school when she reaches that age. At this time, the goal is to provide her enough mobility to experience social activities similar to those of other children her age.

A concentrated team effort was, and will continue to be, essential for managing SF's mobility and prosthetic needs. Choosing appropriate items and training SF in their use required input from physicians, physical and occupational therapists, pros-

sthetists, engineers, orthotists, nurses, social workers and family members. SF's daily needs, developmental abilities and family circumstances, as well as her orthopaedic status, influenced the decision making. Creative thinking and cooperative efforts enabled this seriously physically handicapped child to achieve some degree of age-appropriate mobility and independence.

ACKNOWLEDGMENTS

The authors gratefully acknowledge the significant contributions to SF's care and management made by her family, Robert Fielden, M.D., David Lawson, Rehabilitation Engineer, Rebecca Lucas, RPT, Michael Pearl, CPO, Kama Norton, BUS, Social Worker, Susan Swanson, OTR, and David Wilkie, Adaptive Equipment Specialist. The photography is by Ken Jandl. This project was partially funded by the Medical Education and Research Association of Gillette Children's Hospital.

NOTES

¹Dow Chemical, Midland, Michigan.

²Apex Foot Products Corp., 200-T Forest Avenue, Englewood, New Jersey.

³A-Bec Electric Wheelchairs, Inc., 20803 Higgins Court, Torrance California 90501.